

Partial-Thickness Tears of the Gluteus Medius: Rationale and Technique for Trans-Tendinous Endoscopic Repair

Benjamin G. Domb, M.D., Rima Michel Nasser, M.D., and Itamar B. Botser, M.D.

Abstract: Tears in the gluteus medius and minimus tendons, often misdiagnosed as trochanteric bursitis, have recently emerged as an important cause of recalcitrant greater trochanter pain syndrome. Advances in endoscopic surgery of the hip have created opportunities to better evaluate and treat pathology in the peritrochanteric compartment. We reviewed the literature on trochanteric pain syndrome and gluteus medius tendon injuries. Existing techniques for endoscopic and open gluteus tendon repair and potential challenges in restoration of abductor function were analyzed. Partial-thickness undersurface tears of the gluteus medius were identified as a common pathologic entity. Although these tears are otherwise analogous to partial-thickness tears of the rotator cuff, the lack of arthroscopic access to the deep side of the gluteus medius tendon represents a unique technical challenge. To address the difficulty in visualizing and thus repairing undersurface tears of the gluteus medius, a novel endoscopic trans-tendinous repair technique was developed. The purposes of this article are to review the anatomy, pathology, and existing repair techniques of gluteus medius tendon tears and to describe the rationale and surgical steps for endoscopic trans-tendinous repair.

Greater trochanteric pain syndrome (GTPS) is a common complaint with an estimated incidence of 1.8 per 1,000 persons.¹ Patients usually present with a dull pain on the lateral aspect of the hip, sometimes with radiation posteriorly and into the thigh. The pain is aggravated by pressure on the area, weight bearing, and resisted hip abduction.

From the Loyola University Stritch School of Medicine (B.G.D.), Chicago, Illinois; and Hinsdale Orthopaedics (B.G.D., R.M.N., I.B.B.), Chicago, Illinois, U.S.A.

B.G.D. has received from Arthrex, Naples, Florida, support exceeding US \$500 related to this research. The other authors report no conflict of interest.

Received May 3, 2010; accepted June 1, 2010.

Address correspondence and reprint requests to Benjamin G. Domb, M.D., Hinsdale Orthopaedics, 1010 Executive Ct, Ste 250, Westmont, IL 60559, U.S.A. E-mail: bendomb@yahoo.com

© 2010 by the Arthroscopy Association of North America

0749-8063/10278/\$36.00

doi:10.1016/j.arthro.2010.06.002

Note: To access the videos accompanying this report, visit the December issue of *Arthroscopy* at www.arthroscopyjournal.org.

Historically, if the pain was associated with tenderness over the area of the greater trochanter, the diagnosis of trochanteric bursitis was presumed. After failure of initial conservative treatment consisting of anti-inflammatory therapy and lifestyle modifications, corticosteroid injections have been commonly used. Surgical treatment has rarely been recommended, and in patients who receive only temporary relief after injections, multiple injections have often been administered. Recent studies have disproved the theory that the pathology underlying the pain is due to inflammation of the bursae.² Tears of the gluteus tendons can be the source of such lateral hip pain³⁻¹⁰ and can cause significant morbidity. However, these tears are often missed, or misdiagnosed as bursitis, resulting in prolonged chronic peritrochanteric pain. Fortunately, better knowledge of the anatomy and pathology, combined with improved techniques in magnetic resonance imaging (MRI), have allowed the clinician to diagnose gluteus medius tears as an underlying source of GTPS.

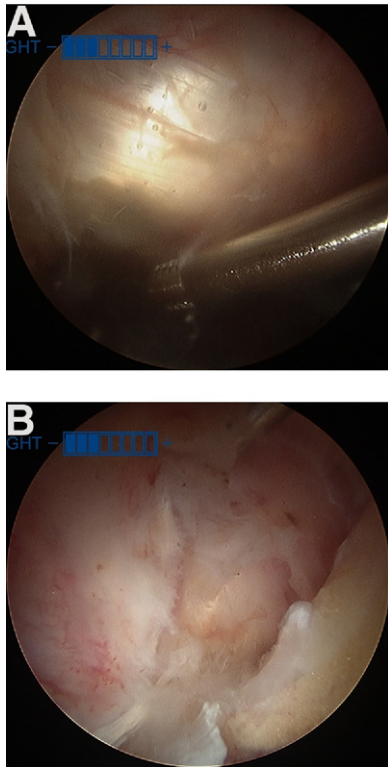


FIGURE 2. Partial undersurface tear of gluteus medius tendon. (A) Arthroscopic image through anterolateral portal of apparently intact gluteus medius tendon after bursectomy. Patient is in supine position. (B) Arthroscopic image through anterolateral portal of same tendon undersurface tear after longitudinal incision through superficial fibers. Patient is in supine position.

medius and minimus tendons, initially described by Bunker et al.¹⁸ and Kagan,¹⁹ have subsequently been the subject of multiple publications.^{3,8,20-23} Although the true prevalence of gluteus complex tears is un-

known, gluteus medius tendon tears may occur in as many as 25% of late middle-aged women and 10% of men in the same age group.¹³ Whereas acute tears of the gluteal tendons may occur, it is believed that degenerative tears are more common.^{11,24} Gluteus medius tears occur more often than gluteus minimus tears.^{8,9} Tears at the insertion of the gluteus medius tendon can be intrasubstance, partial, or complete.¹⁸ Connell et al.⁹ showed that partial tears were far more common.

In our experience most partial-thickness tears encountered were undersurface tears. Because most of the pathology is covered by intact tendon, the tears may go unnoticed, because they are not directly visible through either an open or endoscopic approach (Fig 2).

A very clear analogy can be drawn between undersurface tears of the gluteus medius and partial-thickness articular-sided tears of the rotator cuff (Table 1). In both cases the tearing occurs on the deep side of the tendon and may not be visible from the superficial side of the tendon. Multiple techniques for repair of partial or intrasubstance shoulder rotator cuff tears have been described. Debridement of these tears did not provide adequate pain relief,^{25,26} so repair was attempted and initially involved completing the tears,²⁷⁻²⁹ which altered the normal footprint of the tendon. Trans-tendinous techniques for PASTA (partial articular supraspinatus tendon avulsion) repair were then introduced that involved debriding and resecting only the diseased portion of the tendon and repairing the tears to the normal footprint.^{30,31} Spencer³² also described an all-inside technique to treat partial articular-sided tears that do not violate the bursal surface.

Although gluteal tendon pathology may be very similar to partial-thickness articular tears of the rotator

TABLE 1. Similarities and Differences Between Shoulder and Hip Rotator Cuffs

	Shoulder Rotator Cuff	Hip Rotator Cuff
Functional anatomy		
Internal rotator	Subscapularis	Iliopsoas
Stabilizers and rotators, initiation and assistance in abduction	Supraspinatus and infraspinatus	Gluteus medius and minimus
Abduction	Deltoid	Tensor fascia lata
Clinical presentation	Pain with motion	Tenderness over lateral aspect of hip
	Tenderness	Weakness in abduction
	Weakness in abduction	
MRI/ultrasound	Visualized on MRI and ultrasound	Visualized on MRI and ultrasound
Mechanism	Degenerative tearing	Degenerative tearing
	Acute trauma	Acute trauma
Arthroscopic evaluation	Articular tears can be visualized as either exposed footprint or delamination	Undersurface tears cannot be easily visualized

cuff of the shoulder, there is at least 1 important difference: the latter can be accessed from both the articular and bursal sides. In contrast, there is no space on the deep side of the gluteus medius analogous to the intra-articular space of the shoulder, from which the undersurface of the tendon can be visualized. Because of the lack of access to the deep side, trans-tendinous repairs of the gluteus medius cannot be performed in the same manner as a PASTA-style repair of the rotator cuff. The lack of access to the deep side poses a unique technical challenge in surgical treatment of undersurface gluteus medius tears.

Another instructive analogy may be drawn between undersurface gluteus medius tears and extensor carpi radialis brevis (ECRB) tears in lateral epicondylitis. ECRB tears generally occur through micro-tearing and subsequent degeneration of tendon tissue on its deep side.³³ We have observed a similar phenomenon in the gluteus medius, where degenerative partial-thickness tearing occurs on the deep side of the tendon, near its bony insertion. Thornton et al.³⁴ proposed a surgical procedure for treatment of partial-thickness undersurface tears of the ECRB. This procedure involves exposure of the deep fibers of the ECRB tendon through a longitudinal split, excision of the pathologic parts of the tendon near its insertion, decortication of the lateral epicondyle, and repair of the ECRB to the bone with suture anchors. This procedure had good to excellent results in all 22 patients who underwent the surgery.

EXISTING TECHNIQUES FOR REPAIR OF GLUTEUS MEDIUS

Open Techniques

Multiple procedures are described to help relieve refractory trochanteric bursitis including open bursectomy, IT band lengthening or release,^{35,36} and trochanteric reduction osteotomy,³⁷ but there is very little in the literature describing specific open repair techniques for gluteus medius and minimus tendon ruptures. Davies et al.³⁸ describe a technique using soft-tissue anchors in the greater trochanter to reattach torn abductors diagnosed by examination and MRI. They had 4 re-ruptures out of 16 repairs, and the patients with no postoperative complications had significant improvement in their pain. Bunker et al.¹⁸ used intraosseous sutures to repair the torn part of the tendon to decorticated bleeding bone with the rationale that simple repair of a tendon tear would be unlikely to heal.

Endoscopic Techniques

As with open techniques, multiple endoscopic procedures have been described to treat lateral-sided pain, including bursectomy,³⁹ IT band release for external snapping hip syndrome,^{40,41} and debridement for treatment of calcific tendonitis of the gluteus medius and minimus.⁴²

Voos et al.⁴³ describe a technique to repair gluteus tendon tears that could be seen from the peritrochanteric compartment. Their technique involves debridement of the edges of the visualized tear and the attachment site on the trochanter. Suture anchors were placed in the footprint of the abductor tendons, with the help of fluoroscopic guidance, and used to repair the torn tendon to the bone. All ten patients who had this procedure had complete relief of their symptoms.⁴³

As discussed previously, partial-thickness undersurface tears present a particular problem, because they are not visible by arthroscopic or open examination from the peritrochanteric space. These partial-thickness tears have been implicated in debilitating GTPS, and therefore the authors believe that a different approach to arthroscopic diagnosis and repair is indicated.

OUR PREFERRED TECHNIQUE: TRANS-TENDINOUS ENDOSCOPIC GLUTEUS MEDIUS DEBRIDEMENT AND REPAIR

Based on our review of the anatomy of undersurface tears of the lateral facet insertion of the gluteus medius, we identified a need for access to the undersurface for debridement of pathologic tissue and repair to the lateral facet. To surmount this challenge, a novel technique was developed for trans-tendinous endoscopic gluteus medius debridement and repair. In the development of this technique, several goals of successful repair were considered (Table 2). The technique incorporates and builds upon previous work on

TABLE 2. Goals and Potential Pitfalls of Trans-Tendinous Endoscopic Gluteus Medius Debridement and Repair

Technique Advantages	Potential Pitfalls
Minimal disruption of normal anatomy	Portal placement Muscle injury
Visualization of intrasubstance and undersurface tears	Difficulty passing and shuttling suture for repair
Secure repair of tears and debridement of pathologic tendon	Incorrect anchor placement

trans-tendinous repairs of the rotator cuff of the shoulder and of the common extensor origin of the elbow. The purpose of this article is to describe the anatomic basis and surgical steps for the trans-tendinous endoscopic gluteus medius debridement and repair technique. Video clips of the technique are available for viewing at www.arthroscopyjournal.org.

Portal Placement

The 70° arthroscope is inserted into the peritrochanteric space through a mid-anterior portal. By aiming just inferior to the vastus ridge under fluoroscopic visualization, the surgeon avoids iatrogenic damage to the gluteus medius insertion (Fig 3). A shaver is then introduced through the anterolateral portal. Trochanteric bursectomy is performed, with care to keep the shaver blades away from the gluteus medius. When the decision is made to proceed with repair, posterolateral and distal peritrochanteric portals are created. These 2 portals are in line with the center of the trochanter, located 3 cm proximal and 3 cm distal, respectively, to the tip of the trochanter (Fig 4A).

Trans-Tendinous Approach and Debridement

The surgeon performs diagnostic endoscopic examination of the peritrochanteric space, visualizing and probing the gluteus medius, gluteus maximus, vastus lateralis, and IT band. A beaver blade is used to create a longitudinal split in the midsubstance of the lateral facet insertion of the gluteus medius. Through this split, the undersurface tearing and pathologic tendon tissue are visible. The arthroscope can be inserted through this split into the gluteus medius bursal space

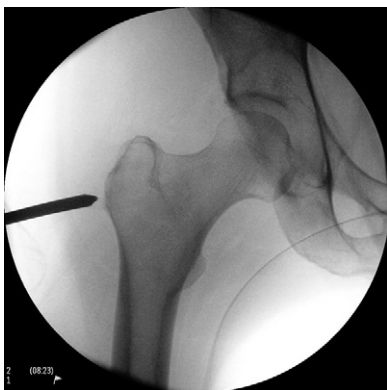

FIGURE 3. Fluoroscopic anteroposterior view of right hip with cannula being aimed just inferior to vastus ridge for peritrochanteric compartment access.

on the deep side of the gluteus medius tendon. From this perspective, the undersurface of the tendon can be viewed in its entirety (Fig 2B). The shaver is used to debride the pathologic tissue and to expose the lateral facet of the greater trochanter (Fig 4B). A bur is used to decorticate the lateral facet to create a bleeding bed of bone for healing of the repaired tendon (Fig 4C).

Trans-Tendinous Repair Technique

With the assistance of fluoroscopic guidance, a 5.5-mm Corkscrew anchor (Arthrex, Naples, FL) is placed through the tendon split in the distal part of the lateral facet footprint (Fig 4D). The Crescent SutureLasso or Birdbeak (Arthrex) is used to pass 1 limb of each suture through the anterior part of the tendon and 1 limb of each suture through the posterior part (Fig 4E). This is then repeated for a second anchor placed in the more proximal part of the lateral facet. All sutures are tied down by use of an arthroscopic knot-tying technique (Fig 4F). This technique results in a side-to-side repair of the longitudinal tendon split while firmly approximating the tendon to the footprint on the lateral facet (Fig 4G).

DISCUSSION

GTPS often responds well to conservative treatment, including anti-inflammatory medication, physical therapy, and steroid injection. In GTPS that is refractory to nonsurgical measures, underlying gluteus tendon injury should be considered. Bard⁴⁴ proposed tendinopathy of the gluteus medius tendon as the chief source of this syndrome and cautioned against overuse of corticosteroid injections without actual firm diagnosis. Gluteus tendinopathy is often misdiagnosed as bursitis and not even regarded as a possible cause of lateral hip pain, as shown by a recent survey of orthopaedic surgeons performed in France.⁴⁵ Increased awareness and better understanding of the pathophysiology of GTPS are key factors that will help the physician consider gluteus tendon tears as a potential reason for the patient's symptoms.

The diagnosis of gluteus tendinopathy or rupture should initially be made clinically. Clinical examination includes palpation for tenderness, Trendelenburg testing,⁴ abduction strength testing, and resisted external rotation in supine (hip flexed 90°) and prone (hip extended) positions.⁴⁶

MRI and ultrasound may be used for confirmation of the diagnosis. Blankenbaker et al.⁴⁷ showed that

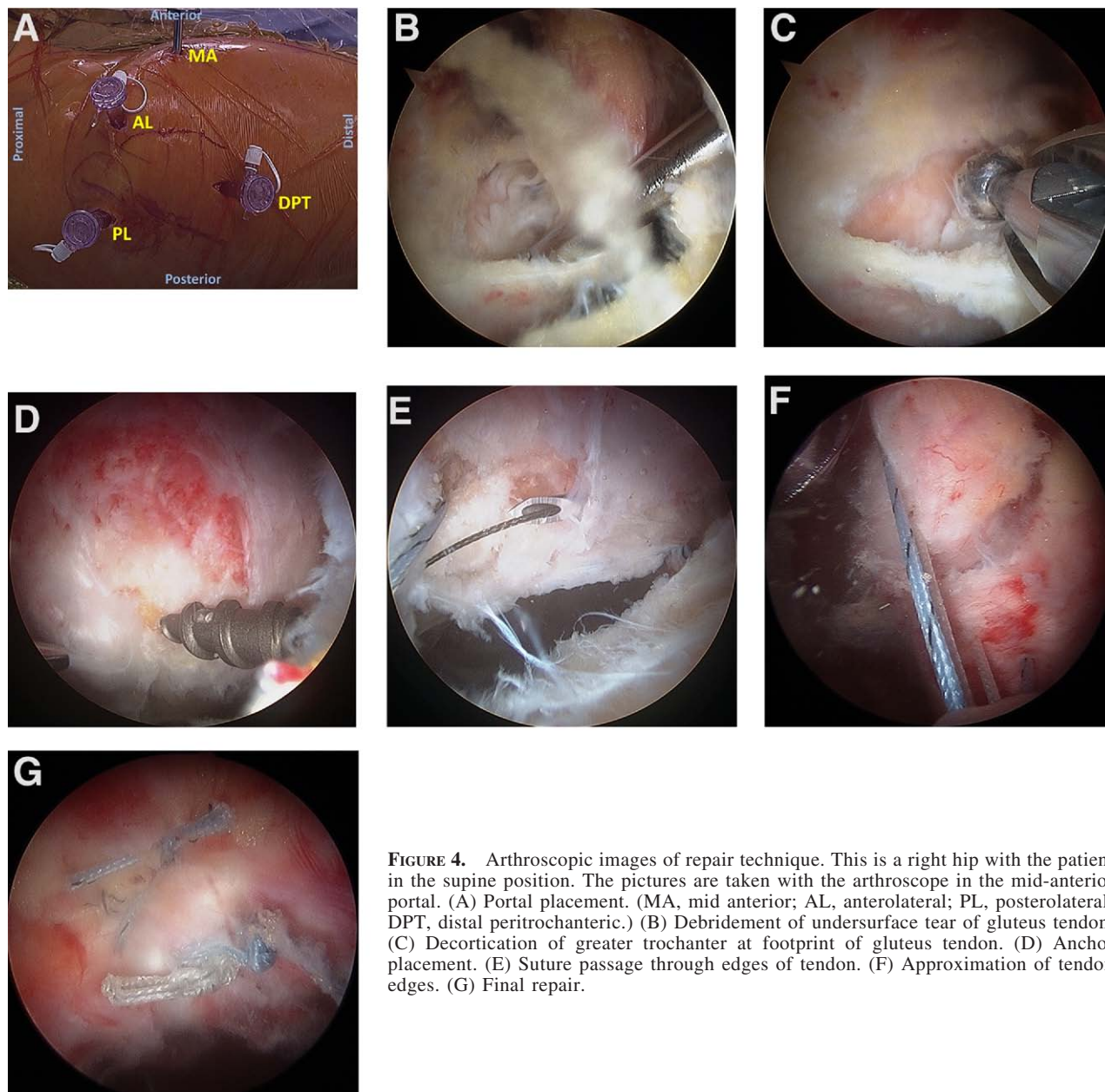


FIGURE 4. Arthroscopic images of repair technique. This is a right hip with the patient in the supine position. The pictures are taken with the arthroscope in the mid-anterior portal. (A) Portal placement. (MA, mid anterior; AL, anterolateral; PL, posterolateral; DPT, distal peritrochanteric.) (B) Debridement of undersurface tear of gluteus tendon. (C) Decortication of greater trochanter at footprint of gluteus tendon. (D) Anchor placement. (E) Suture passage through edges of tendon. (F) Approximation of tendon edges. (G) Final repair.

findings of peritrochanteric inflammation on MRI might not necessarily correlate with actual disease. They evaluated MRI scans of 256 consecutive hips without any knowledge of clinical symptoms. After the data were collected, they found that all hips with trochanteric pain (16) had evidence of peritrochanteric abnormalities on MRI. However, of 240 asymptomatic hips, 212 (88%) had similar positive MRI findings. In contrast, 88% of hips with trochanteric symptoms had MRI findings consistent with gluteus tendinopathy,

whereas only 50% of asymptomatic hips had such findings. Although these findings suggest that gluteus tendinopathy may be a more significant MRI finding than trochanteric bursitis, the high percentage of abnormal findings in asymptomatic patients underlines the importance of clinical evaluation.⁴⁷

We present a novel technique to debride and repair gluteus tendinosis and partial tearing endoscopically (Fig 5 and Videos 1-4, available at www.arthroscopyjournal.org). To our knowledge, the only

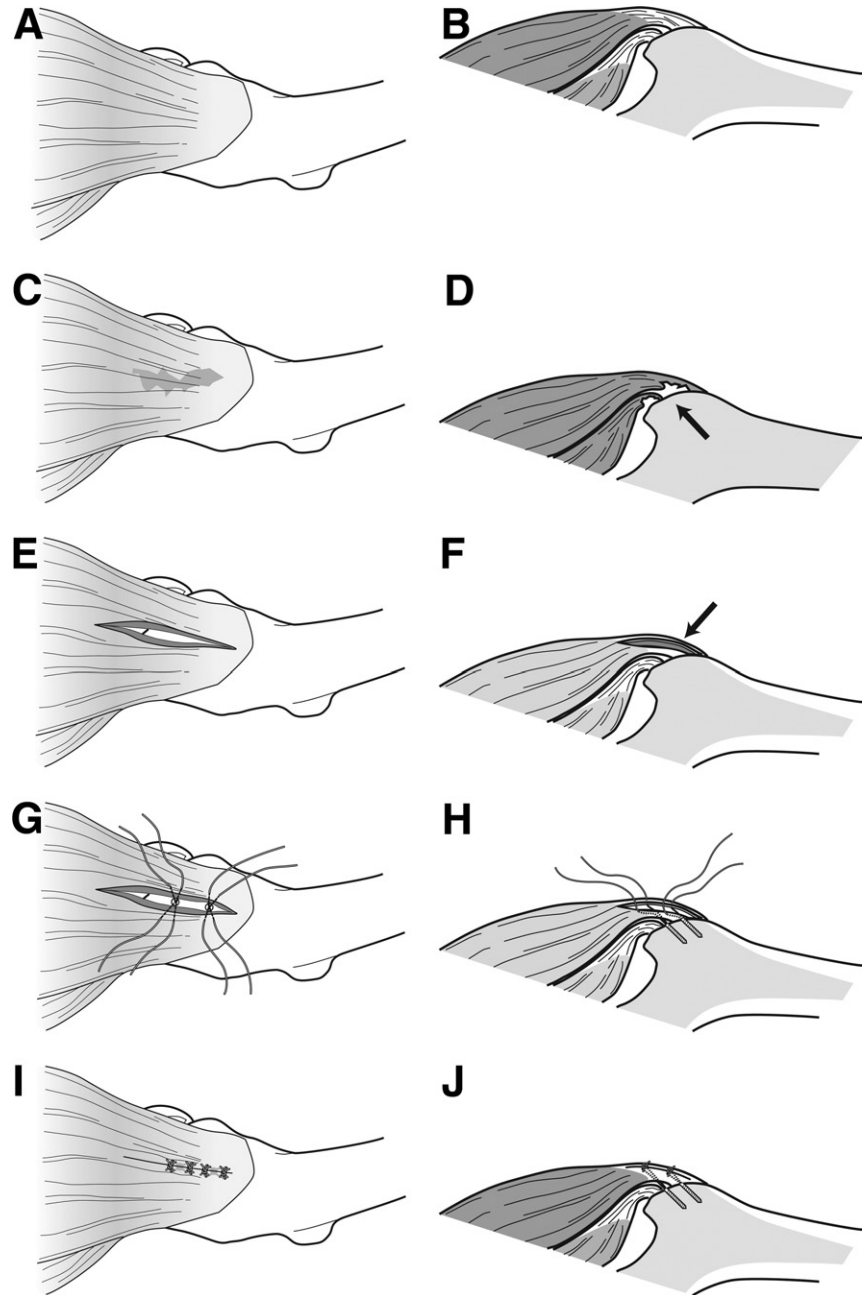


FIGURE 5. Schema of surgical repair technique in a right hip. Proximal is left, and distal is right. (A) Superficial view of intact gluteus tendon. (B) Cross-sectional view of intact gluteus tendon. (C) Superficial view of undersurface gluteus tendon tear. (D) Cross-sectional view of undersurface gluteus tendon tear (arrow). (E) Superficial view of longitudinal incision along gluteus tendon fibers. (F) Cross-sectional view of longitudinal incision along gluteus tendon fibers (arrow). (G) Superficial view of anchor placement and suture passage through tendon edges, after debridement of tear and decortication of bony bed. (H) Cross-sectional view of anchor placement and suture passage. (I) Superficial view of final repair of gluteus tendon. (J) Cross-sectional view of final repair of gluteus tendon.

other endoscopic gluteus tendon repair technique, described by Voos et al.,⁴³ involved tears that were either full thickness or at least grossly visible from the peritrochanteric space. By approaching the tendon through a longitudinal split in line with its fibers, we are able to visualize and treat intrasubstance and undersurface tears without affecting the integrity and strength of the tendon itself. Using anchors in a well-prepared bed of bone and putting the suture through the tear and the split allow for a secure repair.

CONCLUSIONS

Often misdiagnosed as trochanteric bursitis, partial tears of the gluteus medius and minimus tendinous insertions onto the greater trochanter can be the source of chronic debilitating lateral hip pain. We present an endoscopic technique that allows visualization, debridement, and repair of these tears with minimal and fully repairable injury to the remaining intact tendon.

REFERENCES

1. Williams BS, Cohen SP. Greater trochanteric pain syndrome: A review of anatomy, diagnosis and treatment. *Anesth Analg* 2009;108:1662-1670.
2. Silva F, Adams T, Feinstein J, Arroyo RA. Trochanteric bursitis: Refuting the myth of inflammation. *J Clin Rheumatol* 2008;14:82-86.
3. LaBan MM, Weir SK, Taylor RS. 'Bald trochanter' spontaneous rupture of the conjoined tendons of the gluteus medius and minimus presenting as a trochanteric bursitis. *Am J Phys Med Rehabil* 2004;83:806-809.
4. Bird PA, Oakley SP, Shnier R, Kirkham BW. Prospective evaluation of magnetic resonance imaging and physical examination findings in patients with greater trochanteric pain syndrome. *Arthritis Rheum* 2001;44:2138-2145.
5. Bewyer D, Chen J. Gluteus medius tendon rupture as a source for back, buttock and leg pain: Case report. *Iowa Orthop J* 2005;25:187-189.
6. Ozcakar L, Erol O, Kaymak B, Aydemir N. An underdiagnosed hip pathology: Apropos of two cases with gluteus medius tendon tears. *Clin Rheumatol* 2004;23:464-466.
7. Kong A, Van der Vliet A, Zadov S. MRI and US of gluteal tendinopathy in greater trochanteric pain syndrome. *Eur Radiol* 2007;17:1772-1783.
8. Kingzett-Taylor A, Tirman PF, Feller J, et al. Tendinosis and tears of gluteus medius and minimus muscles as a cause of hip pain: MR imaging findings. *AJR Am J Roentgenol* 1999;173:1123-1126.
9. Connell DA, Bass C, Sykes CA, Young D, Edwards E. Sonographic evaluation of gluteus medius and minimus tendinopathy. *Eur Radiol* 2003;13:1339-1347.
10. Chung CB, Robertson JE, Cho GJ, Vaughan LM, Copp SN, Resnick D. Gluteus medius tendon tears and avulsive injuries in elderly women: Imaging findings in six patients. *AJR Am J Roentgenol* 1999;173:351-353.
11. Dwek J, Pfirrmann C, Stanley A, Pathria M, Chung CB. MR imaging of the hip abductors: Normal anatomy and commonly encountered pathology at the greater trochanter. *Magn Reson Imaging Clin N Am* 2005;13:691-704, vii.
12. Pfirrmann CW, Chung CB, Theumann NH, Trudell DJ, Resnick D. Greater trochanter of the hip: Attachment of the abductor mechanism and a complex of three bursae—MR imaging and MR bursography in cadavers and MR imaging in asymptomatic volunteers. *Radiology* 2001;221:469-477.
13. Robertson WJ, Gardner MJ, Barker JU, Boraiah S, Lorich DG, Kelly BT. Anatomy and dimensions of the gluteus medius tendon insertion. *Arthroscopy* 2008;24:130-136.
14. Gottschalk F, Kourosh S, Leveau B. The functional anatomy of tensor fasciae latae and gluteus medius and minimus. *J Anat* 1989;166:179-189.
15. Lequesne M, Mathieu P, Vuillemin-Bodaghi V, Bard H, Djian P. Gluteal tendinopathy in refractory greater trochanter pain syndrome: Diagnostic value of two clinical tests. *Arthritis Rheum* 2008;59:241-246.
16. Naito M, Ogata K, Emoto G. The blood supply to the greater trochanter. *Clin Orthop Relat Res* 1996:294-297.
17. Najima H, Gagey O, Cottias P, Hutten D. Blood supply of the greater trochanter after trochanterotomy. *Clin Orthop Relat Res* 1998:235-241.
18. Bunker TD, Esler CN, Leach WJ. Rotator-cuff tear of the hip. *J Bone Joint Surg Br* 1997;79:618-620.
19. Kagan A II. Rotator cuff tears of the hip. *Clin Orthop Relat Res* 1999:135-140.
20. Lonner JH, Van Kleunen JP. Spontaneous rupture of the gluteus medius and minimus tendons. *Am J Orthop (Belle Mead NJ)* 2002;31:579-581.
21. Gabrion A, Vernois J, Havet E, Mertl P, de Lestang M. Gluteus medius tendon tear and degenerative hip disease. *Rev Chir Orthop Reparatrice Appar Mot* 2003;89:640-642 (in French).
22. Schuh A, Zeiler G. Rupture of the gluteus medius tendon. *Zentralbl Chir* 2003;128:139-142; discussion 143 (in German).
23. Chebil M, Ben Maitigue M, Haddad N, et al. Arthroscopy of the shoulder. Technics and indications. About 64 cases. *Tunis Med* 2007;85:519-523 (in French).
24. Karpinski MR, Piggott H. Greater trochanteric pain syndrome. A report of 15 cases. *J Bone Joint Surg Br* 1985;67:762-763.
25. Weber SC. Arthroscopic debridement and acromioplasty versus mini-open repair in the management of significant partial-thickness tears of the rotator cuff. *Orthop Clin North Am* 1997;28:79-82.
26. Budoff JE, Nirschl RP, Guidi EJ. Debridement of partial-thickness tears of the rotator cuff without acromioplasty. Long-term follow-up and review of the literature. *J Bone Joint Surg Am* 1998;80:733-748.
27. Rudzki JR, Shaffer B. New approaches to diagnosis and arthroscopic management of partial-thickness cuff tears. *Clin Sports Med* 2008;27:691-717.
28. Ellman H. Diagnosis and treatment of incomplete rotator cuff tears. *Clin Orthop Relat Res* 1990:64-74.
29. Weber SC. Arthroscopic debridement and acromioplasty versus mini-open repair in the treatment of significant partial-thickness rotator cuff tears. *Arthroscopy* 1999;15:126-131.
30. Waibl B, Buess E. Partial-thickness articular surface supraspinatus tears: A new transtendon suture technique. *Arthroscopy* 2005;21:376-381.
31. Lo IK, Burkhart SS. Transtendon arthroscopic repair of partial-thickness, articular surface tears of the rotator cuff. *Arthroscopy* 2004;20:214-220.
32. Spencer EE Jr. Partial-thickness articular surface rotator cuff tears: An all-inside repair technique. *Clin Orthop Relat Res* 2010;468:1514-1520.
33. Calfee RP, Patel A, DaSilva MF, Akelman E. Management of lateral epicondylitis: Current concepts. *J Am Acad Orthop Surg* 2008;16:19-29.
34. Thornton SJ, Rogers JR, Prickett WD, Dunn WR, Allen AA, Hannafin JA. Treatment of recalcitrant lateral epicondylitis with suture anchor repair. *Am J Sports Med* 2005;33:1558-1564.
35. Chirputkar K, Weir P, Gray A. Z-lengthening of the iliotibial band to treat recalcitrant cases of trochanteric bursitis. *Hip Int* 2007;17:31-35.
36. Provencher MT, Hofmeister EP, Muldoon MP. The surgical treatment of external coxa saltans (the snapping hip) by Z-plasty of the iliotibial band. *Am J Sports Med* 2004;32:470-476.
37. Govaert LH, van der Vis HM, Marti RK, Albers GH. Trochanteric reduction osteotomy as a treatment for refractory trochanteric bursitis. *J Bone Joint Surg Br* 2003;85:199-203.
38. Davies H, Zhaeentan S, Tavakkolizadeh A, Janes G. Surgical repair of chronic tears of the hip abductor mechanism. *Hip Int* 2009;19:372-376.
39. Baker CL Jr, Massie RV, Hurt WG, Savory CG. Arthroscopic bursectomy for recalcitrant trochanteric bursitis. *Arthroscopy* 2007;23:8278-32.
40. Ilizaliturri VM Jr, Martinez-Escalante FA, Chaidez PA, Camacho-Galindo J. Endoscopic iliotibial band release for external snapping hip syndrome. *Arthroscopy* 2006;22:505-510.
41. Farr D, Selesnick H, Janecki C, Cordas D. Arthroscopic bursectomy with concomitant iliotibial band release for the treatment of recalcitrant trochanteric bursitis. *Arthroscopy* 2007;23:905.e1-905.e5. Available online at www.arthroscopyjournal.org.
42. Kandemir U, Bharam S, Philippon MJ, Fu FH. Endoscopic treatment of calcific tendinitis of gluteus medius and minimus. *Arthroscopy* 2003;19:E4.
43. Voos JE, Rudzki JR, Shindle MK, Martin H, Kelly BT. Arthroscopic anatomy and surgical techniques for peritrochanteric space disorders in the hip. *Arthroscopy* 2007;23:1246.e1-1246.e5. Available online at www.arthroscopyjournal.org.

44. Bard H. Tendinopathy of the gluteus medius tendon. *Rev Prat* 2009;59:463-468 (in French).
45. Cormier G, Berthelot JM, Maugars Y. Gluteus tendon rupture is underrecognized by French orthopedic surgeons: Results of a mail survey. *Joint Bone Spine* 2006;73:411-413.
46. Lequesne M, Djian P, Vuillemin V, Mathieu P. Prospective study of refractory greater trochanter pain syndrome. MRI findings of gluteal tendon tears seen at surgery. Clinical and MRI results of tendon repair. *Joint Bone Spine* 2008;75:458-464.
47. Blankenbaker DG, Ullrick SR, Davis KW, De Smet AA, Haaland B, Fine JP. Correlation of MRI findings with clinical findings of trochanteric pain syndrome. *Skeletal Radiol* 2008; 37:903-909.